

PHILOSOPHICAL  
TRANSACTIONS.

---

XIV. *On the coagulation by heat of the fluid blood in an aneurismal tumour.* By Sir EVERARD HOME, Bart. V. P. R. S.  
*Communicated January 23, 1826.*

Read March 2, 1826.

IN a case of aneurism in the external iliac artery, in Chelsea Hospital, for the cure of which I tied the femoral artery below the sac, on the 16th September 1825; upon finding that this operation neither diminished the pulsation, nor arrested the increase of the size of the tumour, I was led to introduce a needle, to which is given the name of *acu punctorium*, into the centre of the tumour where the pulsation was most violent, and the fluid state of the blood most distinctly felt: the needle was passed through a small orifice in a bar of steel three inches long, the skin of the thigh was guarded by cork, and the needle was heated through the medium of the steel by a spirit lamp. In a few minutes the patient felt heat and pain in the centre of the tumour, but not very severe, so that the application was continued for fifteen minutes, during which the pulsation in the tumour was diminished; on withdrawing the needle the

MDCCCXXVI.

2 C

orifice was marked by a single drop of coloured serum. In half an hour intense pain was felt in the thigh; but this was not only removed in ten minutes by 20 drops of laudanum, but the thigh and leg became more easy than they had been for the previous twelve hours, and the throbbing in the sac was reduced to an undulation.

This application of heat was not resorted to till the 28th day after taking up the femoral artery, in which time the swelling had increased in size very considerably. The man was 43 years of age, had served 18 years in the 14th dragoon guards, and was a hard drinker. For two days the tumour was easy, and the pulsation had become less under the punctured part than higher up towards the belly. The tumour not diminishing, the operation was repeated on the 34th day from tying the artery; the needle and bar of steel double the size of those before used, and the application continued 35 minutes. The internal heat was greater than before, and the pulsation in the tumour much diminished. The needle was with difficulty withdrawn, a coagulum as hard as sealing-wax the size of a pin's head being firmly attached to the middle of the needle. The pain the operation produced subsided in ten minutes; the internal heat continued 24 hours, and the tumour had now a solid feel: he was quite easy for two days, but on the third the pain and pulsation returned, also the inward pain in a still greater degree than while the needle was immersed, and the tumour was extremely tense. Under these circumstances, on the 44th day after tying the femoral artery, I repeated the application of the *acu punctorium* with a needle and steel double the size of those last employed: the heat felt internally was very great, but the

pain was not much increased : after it had been immersed 20 minutes the pulsation all at once stopped, and the needle was immediately withdrawn ; the pain in ten minutes went off, and the patient was quite easy. From this time there was no pulsation in the tumour, which to the feel appeared solid, and therefore I considered the progress of the aneurism arrested ; this was in some measure proved by the pulsation remaining violent in the external iliac artery down to the part pressed upon by the sac, but no further.

Although the patient was free from pain, took his usual allowance of food, and relished his wine and porter as much as before, the foot about the 50th day became cold to the touch, the thigh and leg œdematous, and about the 60th day vesications made their appearance on the foot and leg ; the skin lost its sensibility, and although he had little or no pain, the weight of the thigh took from him all power of moving it.

These symptoms were the forerunners of mortification, the pressure from the tumour above preventing the leg from receiving a sufficient supply of nourishment ; they did not however increase, and he remained in nearly the same state till the 90th day, when he died.

The upper part of the thigh, which had been regularly measured, was found on the 44th day to be 24 inches, and remained of the same size at his death, three inches and an half beyond that of the other.

On the examination of the parts after death, the external iliac artery was found to pass down in the front of the aneurismal sac ; it was pervious in its course to the part where the ligature had been made on the femoral trunk ; there it

was plugged up by a small coagulum, beyond which it was impervious. The opening into the sac was on the posterior part, and was one inch in length. The coagulum formed by the heated needle had so unusual an appearance and texture, that it is shown in the annexed drawing. The upper portion of the sac occupied a part of the cavity of the pelvis, and by its pressure prevented the branches of the internal iliac artery from supplying the thigh with blood.

The coagulum in contact with the sac was the same as is usually met with in large aneurismal tumours; within that there were innumerable thin firm lamina, and the innermost portion was in the state of jelly.

It is a circumstance which could not have been foreseen, but one highly satisfactory to myself, that had I attempted to tie the artery above the formation of the aneurismal sac, I must have failed, since the sac extended higher than the division of the iliac artery into the external and internal, so that the external branch could not be secured without wounding the sac, which would have proved fatal; and in the space above, between the division into two iliacs, and the bifurcation of the aorta, there is an ossification an inch long; so that if the artery had been secured there, when the ligature separated, the patient must have bled to death. It may be said, that I might have taken up the aorta above the bifurcation; but I have made up my mind to let those diseases that require tying the aorta, which come under my care, take their course.

From the ossifications met with on the arterial trunks so much nearer the heart than the aneurismal sac, and a similar ossification having been formed in the femoral artery in the

middle of the thigh, where it was taken up by Mr. HUNTER in the first instance in which he performed that operation for the cure of popliteal aneurism, we learn that in those individuals liable to aneurism, the larger trunks are more disposed to ossification than common, and therefore the tying such trunks is attended with no inconsiderable risk of hæmorrhage when the ligature comes away.

From the present case of aneurism, and Mr. HUNTER's, in which the success was complete, we find the contents of the sac are less readily absorbed than was believed. In proof of this, I have annexed a drawing of the natural size, taken from the remaining tumour of the popliteal artery of the patient on whom Mr. HUNTER first took up the femoral artery for the cure of aneurism in the ham, in the year 1785. The patient died of a fever 20 months after the operation, which afforded an opportunity of ascertaining the slow progress that had been made in the absorption of the contents of the aneurismal sac.\*

From the statement that has been given, I trust that I have fully proved that the heated acu punctorium can coagulate the fluid blood contained in the aneurismal sac; and in doing so, is not productive of any local or constitutional symptoms that should prevent its being employed for that purpose.

\* Vide Trans. of a Society for Promoting Med. and Chirurg. Knowledge, vol. i. p. 138.

---

## EXPLANATION OF THE PLATES.

## PLATE III. An anterior view of the aneurismal sac.

Fig. 1. A small portion of the aorta ; the division into the two iliac arteries. The sub-division into the external and internal branches. The external iliac artery traced along its course to the opening into the sac. The upper part of the femoral artery slit open, from the lower orifice in the sac to the part where it became obliterated by the coming away of the ligature.

Fig. 2. The lower part of the aorta slit open ; also the common trunk of the iliac artery, to show that the internal membranes of both have begun to ossify. The figures are of the natural size.

## PLATE IV. An internal view of the aneurismal sac.

Fig. 1. The aorta and external iliac passing on the outside of the aneurismal sac. The lamina of the coagulum first formed, and resembling those met with in other aneurismal tumours. The opening into the arterial trunk from the coats having given way for the space of one inch, exposing the upper and lower orifice of the artery ; and showing that the sac adhered to the artery even higher than the going off of the internal iliac.

Fig. 2. A small portion of the blood coagulated by the heated needle, which has a foliated structure, the leaves thin, compact, and connected together by thread-like filaments. Both these figures of the natural size.

Fig. 3. One of these leaves magnified ten diameters ; its surface studded over with nodules of coagulable lymph, like so many drops of melted wax.

Fig. 1.

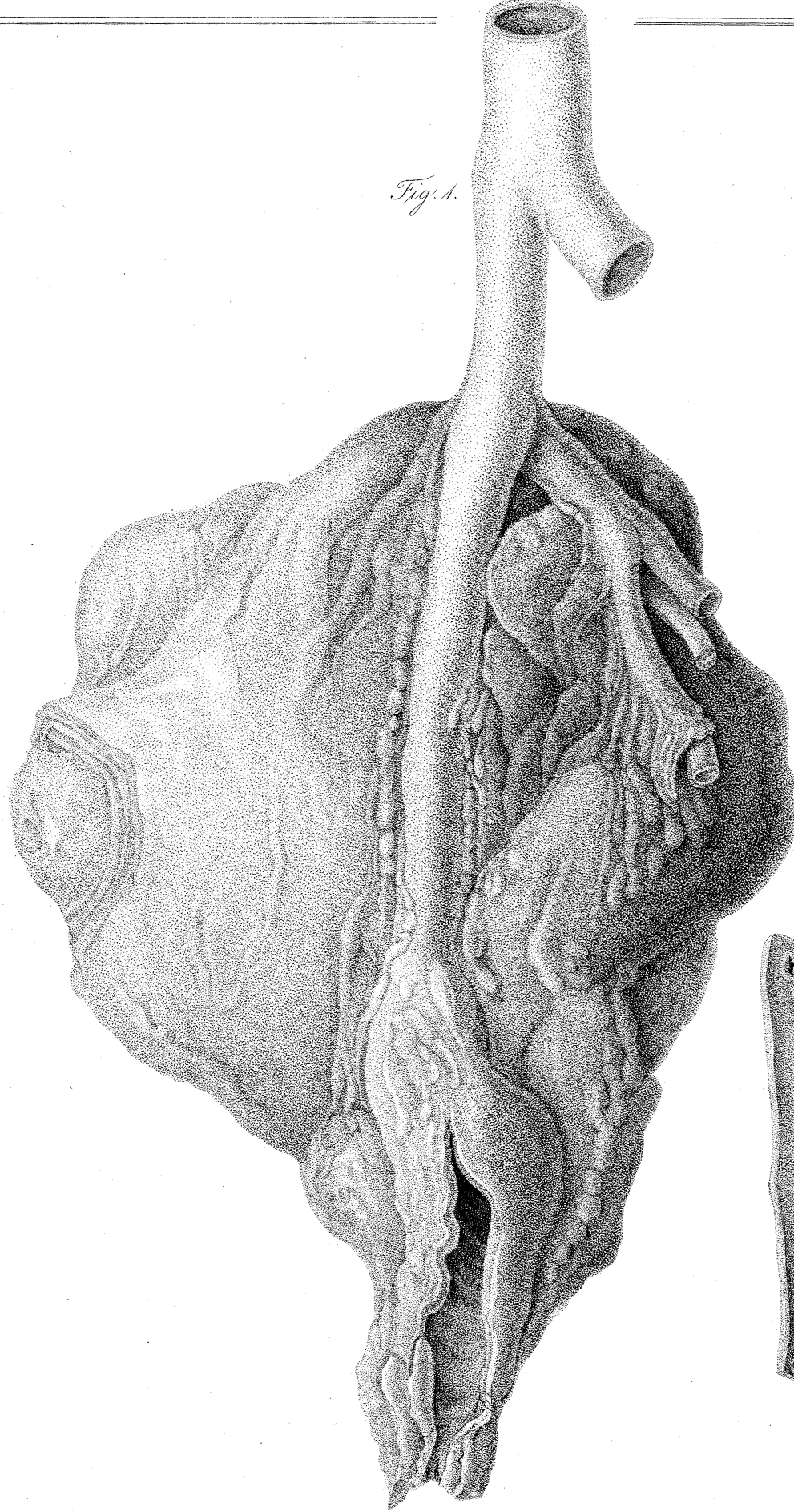
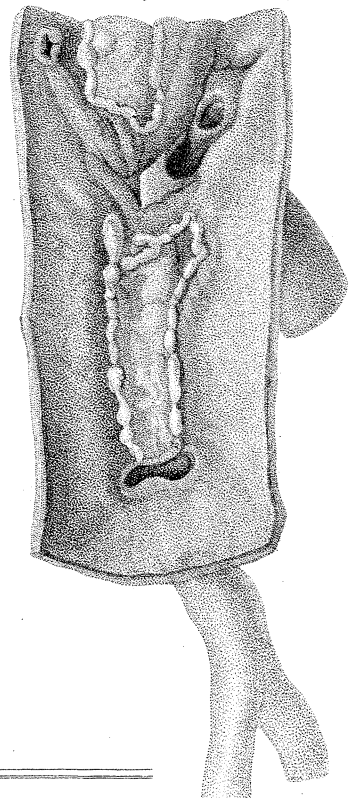


Fig. 2.



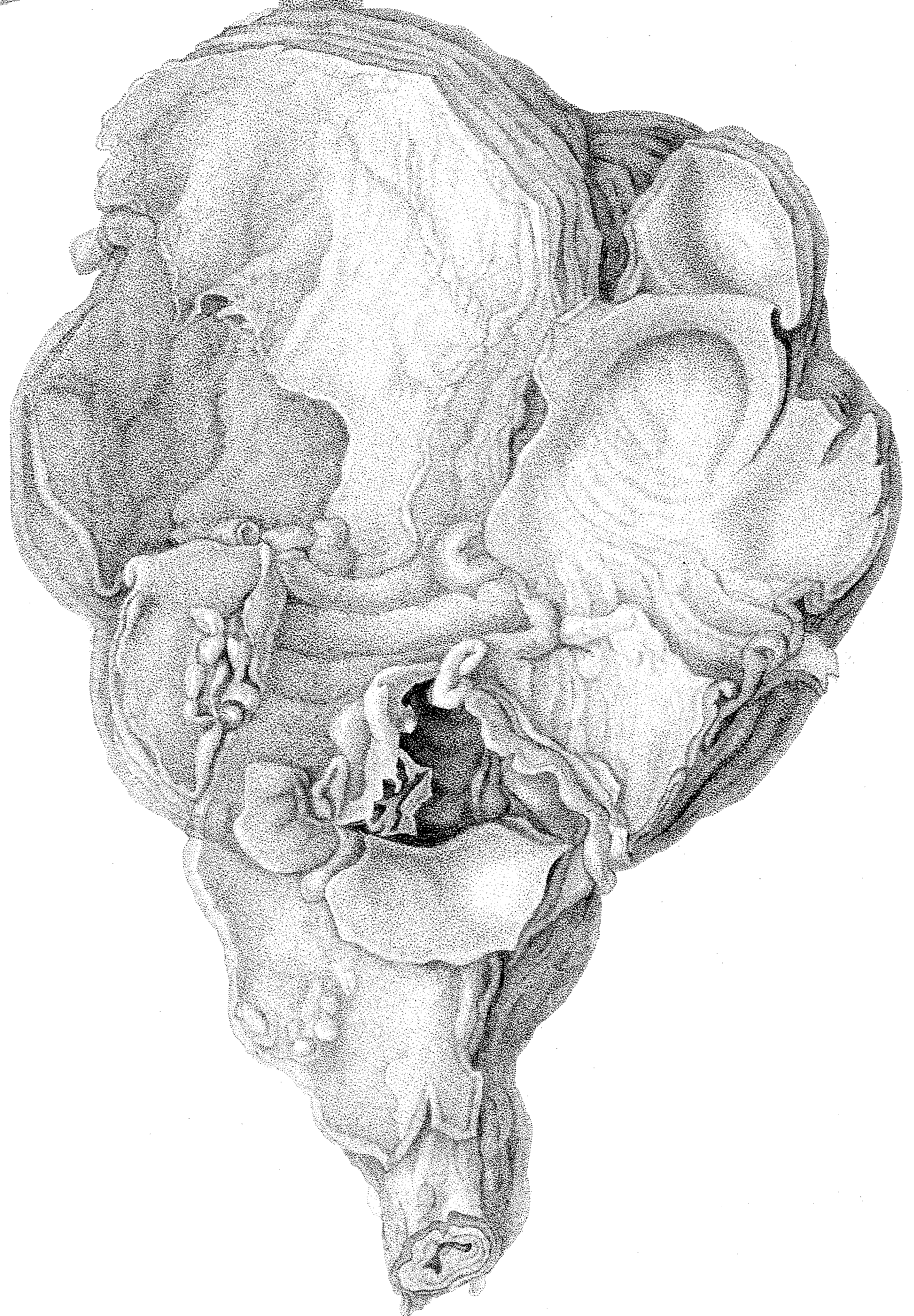
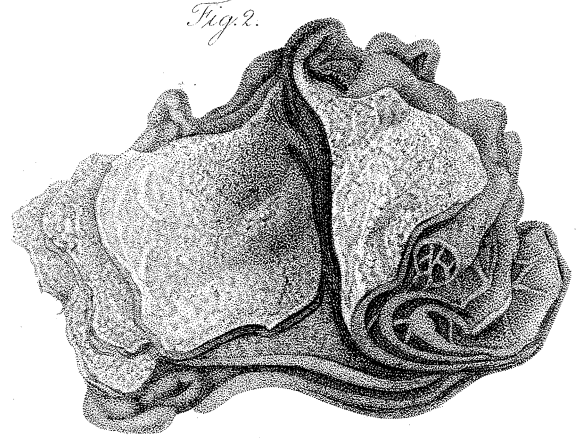
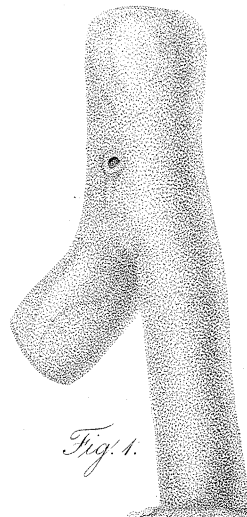
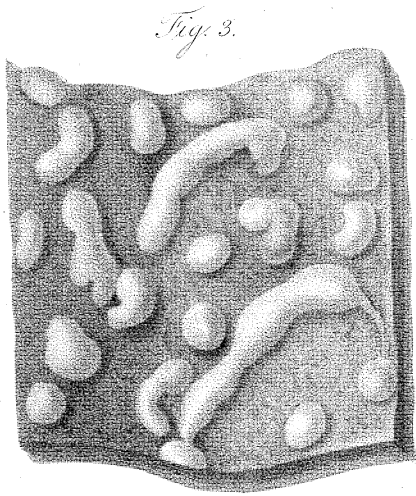




Fig. 1.

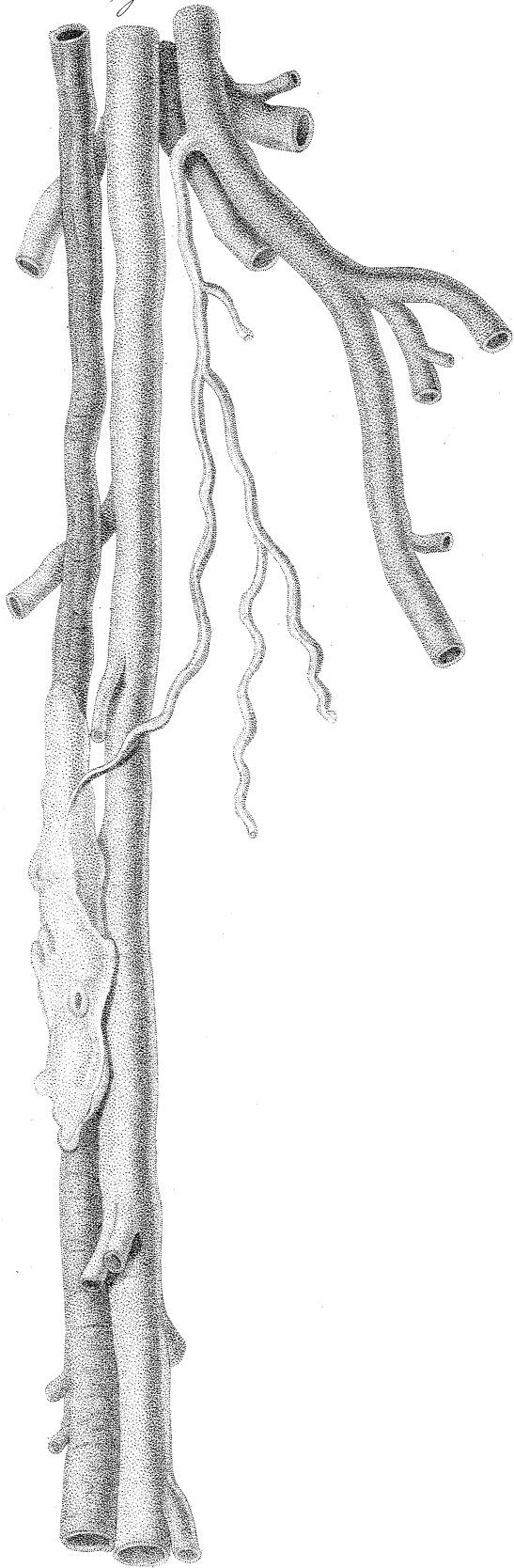


Fig. 2.

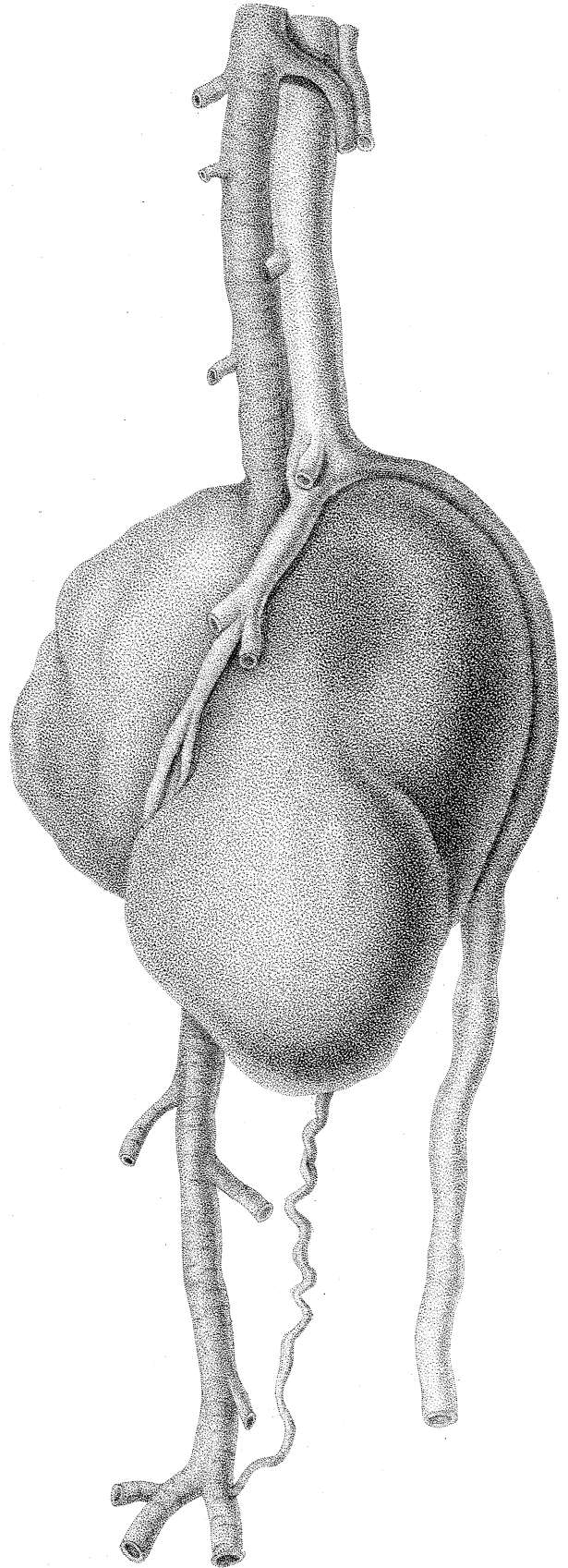


PLATE V.

A representation of the appearance of the remains of the tumour twenty months after the femoral artery had been tied by Mr. HUNTER, in the first case in which he performed that operation for the cure of popliteal aneurism, in the year 1785, at St. George's Hospital. The case was published in 1793, in the first volume of the Transactions of a Society for the Improvement of Medical and Chirurgical Knowledge, but no engraving accompanied that account. That now given is taken from the parts removed from the body after death, which are rendered distinct by having been injected.

Fig. 1. Shows the femoral artery, the canal of which had been rendered impervious from the going off of the large muscular branch called profunda, down to where the ligature had been tied, and there it was ossified. Below this it retained its natural size. There is a small branch from the arteria profunda anastomosing with the femoral trunk immediately below the impervious portion, at the part where the coats afterwards became ossified. The femoral vein accompanies the artery.

Fig. 2. represents the continuation of the femoral artery, showing the dilatation into the aneurismal sac; the size of which is much greater than could have been expected had the absorption gone on with the same activity as in naturally formed parts, 20 months, after the disease had been put a stop to.

Below the aneurismal tumour is a large anastomosing branch from the profunda, with the trunk of the popliteal artery before its division. The veins are spread over the tumour.

*On the effect of heated iron upon fluid blood out of the body.*

THAT I might ascertain the effect of heated iron immediately after it was applied to fluid blood, I bored a hole in the centre of the bottom of a horn cup, through which the same acu punctorium used in the case of aneurism was passed up into the middle of the vessel; and when it was heated by the same bar of iron and spirit lamp, three ounces of blood were received from the arm into the cup, and the heat continued for half an hour, after which the blood was left at rest for 24 hours.

The coagulum had no buff on the surface. When a perpendicular section was made of it, the mass of the red coagulum was interspersed with minute white particles of coagulable lymph, and that part in contact with the needle, for the space of half an inch round, was in the same state as is represented in the drawing of the aneurismal coagulum. To carry on this investigation with pieces of iron, the heat of which was ascertained, I made the following experiment: three pieces of iron, weighing an ounce each, with iron handles covered with wood, were placed in separate cups, and blood from the arm immediately received into them to the amount of three ounces. In the first, the iron was red hot, in the second, the red colour had just gone off, and the third was taken out of boiling water. In five minutes the heat of each portion of blood was ascertained by the thermometer, the pieces of iron being removed. No. 1. was  $110^{\circ}$ , No. 2.  $105^{\circ}$ , No. 3.  $85^{\circ}$ , the atmosphere  $55^{\circ}$ . After standing 24 hours, perpendicular sections were made of them.

No. 1. had separated seven drams of serum, had a greyish film  $\frac{1}{40}$ th of an inch thick; the coagulium was coloured, loose in its texture, interspersed with specks of white coagulable lymph; and at the lower part there was a cell, the shape of the piece of iron, the sides of which had the same frosted flocculent appearance seen in the drawing of the aneurism. No. 2. had separated 12 drams of serum, had a film  $\frac{1}{5}$  of an inch thick, the coagulium was more solid, coloured, interspersed with specks of coagulable lymph, and had a cell in all respects like that in No. 1.

No. 3. had separated 12 drams of serum, had a buffy coat, much cupped,  $\frac{1}{8}$  of an inch thick; the coloured coagulium very solid, and no cavity was found where the iron had been situated.

To determine the effect of lower temperature, I made a similar experiment with three leaden ounce balls, 1st heated to  $200^{\circ}$ , 2d to  $160^{\circ}$ , 3d to  $120^{\circ}$ . At the end of 24 hours, the balls having been left in the cups, No. 1. had a film of buff  $\frac{1}{20}$ th part of an inch, separated 4 drams of serum, round the cavity surrounding the ball a film  $\frac{1}{40}$ th of an inch. No. 2. had a film  $\frac{1}{24}$ th of an inch, serum  $6\frac{3}{4}$  drams, round the ball no film. No. 3. buffy and cupped, the buff  $\frac{1}{6}$ th of an inch, whiter and tougher than the other. The overplus blood drawn into a porringer not in the least buffy.

From these experiments, blood is rendered buffy at the top by a heat of  $120^{\circ}$ , and when poured on substances heated above  $212^{\circ}$  the coagulable lymph is separated where it comes in contact with the heated body.

It is a fact ascertained, that when blood is drawn from the arm into a cup immersed in boiling water, which is kept for

some hours at that heat, does not form a complete coagulum; but if drawn into a cup immersed in ice and left there, in 24 hours I found the surface had a buffy coat  $\frac{3}{8}$  of an inch thick; and although 5 drams of serum had separated, the coagulum was so loose as hardly to hold together.

*A new fact respecting buffy blood after venesection.*

It has been generally believed that the cupped appearance met with on the surface of the coagulation of blood drawn from the arm, arises from the coagulable lymph, when separated from the other parts of the blood, having a greater contractile power than when intimately mixed with them.

In a patient who had an affection of the brain in consequence of an injury to the skull from a wooden shovel, when 35 years of age, no symptoms came on for 8 months. He then had fits, and head-ache, which nothing relieved : he was bled to the amount of 68 oz. in 13 days ; but the last two cups, although equally buffy with all the others, were not cupped, which took my attention. The appearance is shown in the annexed drawing, proving that the coagulable lymph has less power of contraction than the other parts of the blood.

The malady was found, by examining the body after death, to be inflammation of one of the convolutions of the right hemisphere of the cerebrum.

In the microscope, the upper portion without colour consisted wholly of globules  $\frac{1}{2,800}$  and  $\frac{1}{3,200}$  parts of an inch in diameter ; the lower coloured portion was entirely made up of globules  $\frac{1}{2,000}$  and  $\frac{1}{2,400}$  parts of an inch in diameter.

PROFESSOR BRANDE, who examined the chemical properties of these different portions, informs me, “ that the upper portion had the usual properties of the albumen of the blood. “ When carefully dried, it assumed the appearance and che-

“ mical characters of horn. The lower coloured portion was  
 “ looser in texture and considerably softer. In dilute acetic  
 “ acid it soon became perfectly gelatinous, and was dissolved  
 “ in it by the aid of a gentle heat. It contained a much  
 “ larger relative proportion of water than the upper portion,  
 “ and shrunk much more when dried, in which state, however,  
 “ it resembled dried albumen. It appears that independent  
 “ of colouring matter, these two portions of coagulum differ  
 “ chiefly from each other in their state of concentration, the  
 “ upper part containing more albumen, and less water, than  
 “ the lower.”

#### EXPLANATION OF PLATE VI.

Fig. 1. The coagulum represented entire. While immersed in the serum the surface was flat, but after remaining a few hours in weak spirit to prevent it from falling to pieces, the surface put on its present appearance.

Fig. 2. A perpendicular section of the same coagulum. Both of these figures are of the natural size.

Fig. 3. A small part of the upper portion of fig. 1. magnified 200 diameters, to show the size of the globules of which it was composed to be from  $\frac{1}{2,800}$  to  $\frac{1}{3,200}$  parts of an inch in diameter.

Fig. 4. A small part of the lower portion, fig. 2. magnified 200 diameters; showing the size of the globules it contained to be from  $\frac{1}{2,000}$  to  $\frac{1}{2,420}$  parts of an inch in diameter, mixed with a coloured gelatinous substance.

Fig. 5. A coagulum of blood taken from the arm of a person labouring under symptoms of inflammation of the

Fig. 1.

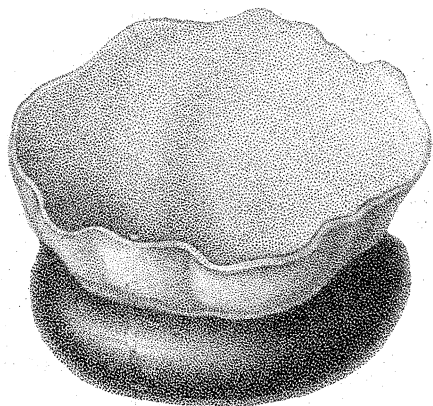


Fig. 2.

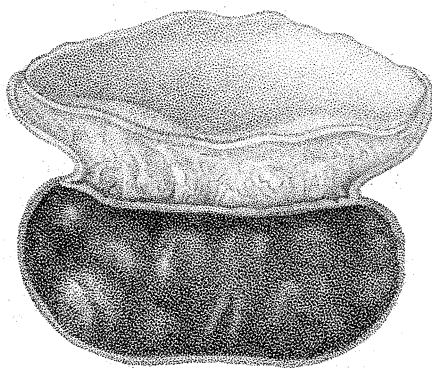
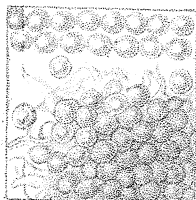
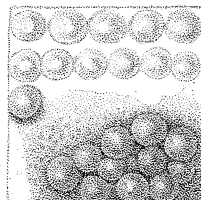


Fig. 3.



From 2800 to 3200 parts of an inch.

Fig. 4.



From 2000 to 2400 parts of an inch.

Fig. 5.

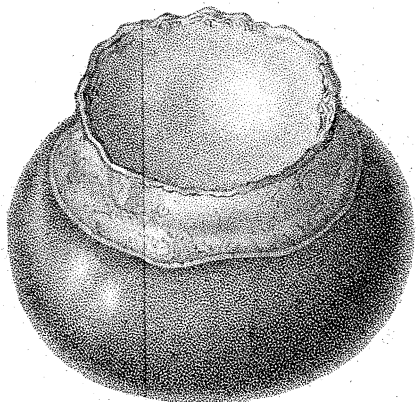
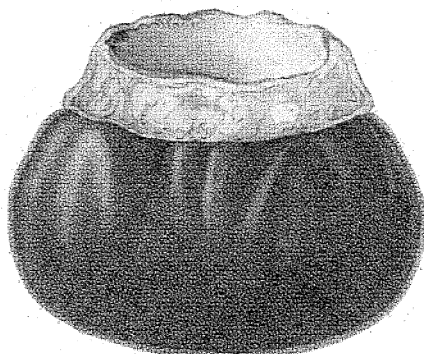


Fig. 6.





lungs; the upper surface is concave; and the coagulable lymph of which it is composed is not entirely free from an admixture of the other component parts of the blood.

Fig. 6. A perpendicular section of fig. 5. The two last figures are represented of their natural size.